

MITO 101 - Audiology

Patrick F.Chinnery, MBBS (Hons), PhD, MRCPATH, FRCP,

Consultant Neurologist, Regional Neuroscience Centre, Newcastle upon Tyne, UK,
Wellcome Trust Senior Fellow in Clinical Science,
Professor of Neurogenetics, University of Newcastle upon Tyne, UK.

Key points

- Impaired hearing is a common feature of mitochondrial disease ^{1,2}, but not all patients with mitochondrial disease develop deafness.
- The hearing impairment often remains undetected for many years and can be overshadowed by more acute or physically disabling aspects of a multi-system mitochondrial disorder ³.
- Hearing impairment in mitochondrial disease often responds well to treatment ⁴. Physicians should therefore keep the auditory system at the front of their mind ***both for new patient consultations and when they review patients with an established diagnosis.***
- Clinical audiometry should be used to detect sub-clinical hearing loss.
- Management includes digital amplification with hearing aids and cochlear implantation.

Clinical investigation of the auditory system

- Mitochondrial disorders are often characterized by cochlear deafness, which can be evaluated using the ***pure tone audiogram*** as a standard clinical tool (Figure). This can be used to diagnose the deafness, and evaluate its pattern and severity.
- The assessment of ***otoacoustic emissions*** (OAE) ⁵ is also helpful. OAEs are sounds produced by an active cochlear mechanism. If absent, this indicates a cochlear component.
- The function of the auditory nerve and ascending pathway can be assessed using brainstem evoked electroencephalogram (EEG) potentials measured in response to sound clicks. This is also called the ***brainstem evoked potential audiometry*** (BEA). Waves I and II of the brainstem potential arise from the auditory nerve whilst waves III to V arise from central brainstem structures below the inferior colliculus in the tectum.
- Structural ***magnetic resonance imaging*** (MRI) allows the identification of lesions within the ascending auditory pathway ⁶.
- Functional magnetic resonance imaging and magnetoencephalography may develop into clinical tools for the assessment of central auditory processing ⁷, but these are currently only used in research.

Clinical features of mitochondrial deafness

- Hearing loss in mitochondrial disease can be isolated (non-syndromic) or part of a complex multisystem disorder (syndromic deafness). The major clinical syndromes are summarized in Table 1.
- The hearing loss is usually peripheral - due to cochlear or auditory nerve dysfunction.
- In patients with a multi-system mitochondrial disorder, the auditory system may also be affected at the brain stem, midbrain or at a higher level in the auditory cortex – but this is often overshadowed by the peripheral lesion.
- The peripheral hearing loss typically affects high frequencies first, followed by intermediate frequencies, and finally involving low frequencies, causing the typical “flat” audiogram seen in a severely deaf individual ^{3,8,9} (Figure).
- OAE are absent in most patients with mitochondrial deafness due to cochlear involvement ^{3,9-11}.

- The severe peripheral component usually prevents physiological stimuli from reaching the brainstem pathways, making it difficult to assess a central component of the deafness. Structural MRI can be used to demonstrate abnormalities within the brainstem and involving the central auditory pathways and the auditory cortex. Evidence of severe central neurological disease will limit the improvement following cochlear implantation.
- Severe deterioration can occur acutely, particularly in patients with the m.3243A>G mutation^{3,9} and patients with the m.1555A>G mutation where it may be related to aminoglycoside exposure¹².

Management of mitochondrial deafness

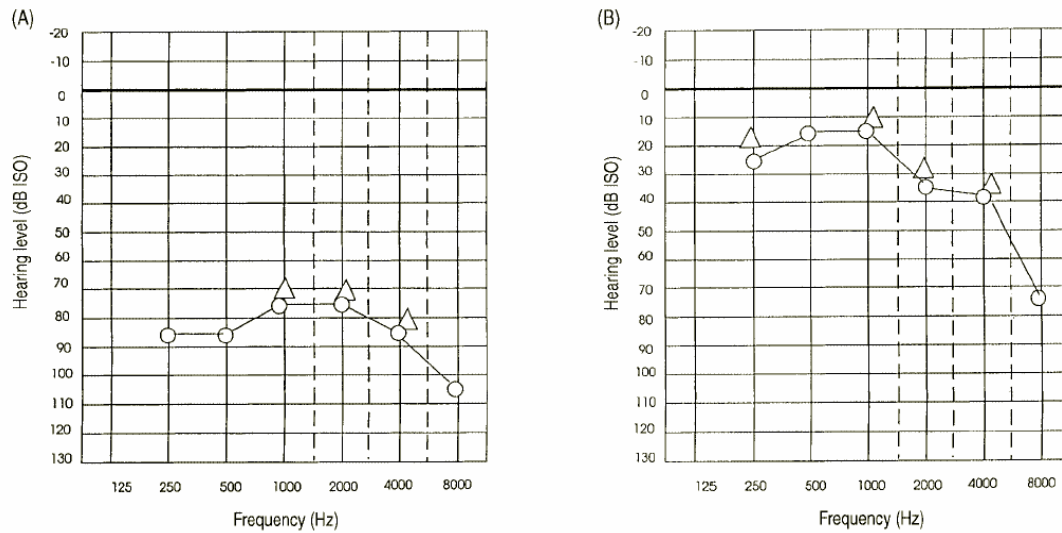
- In most patients, the primary deficit is cochlear and responds well to single or binaural amplification
- A poor response to amplification could be due to additional central auditory involvement (such as the brainstem and connections) or co-incidental middle-ear disease.
- Always ask about tinnitus, because tinnitus masking may improve auditory function.
- Patients with a severe binaural defect that does not respond well to amplification should be considered for cochlear implantation. This has been successful in many patients with isolated and syndromic deafness due to mitochondrial disease^{9,13-18}, with approximately ~2/3 able to converse on the telephone following the surgery¹⁸
- Although complications are rare, the cochlear implantation should only be undertaken with caution. Close involvement of a mitochondrial physician is essential to identify systemic features of mitochondrial disease before, during and after surgery which could compromise the outcome.
- Cognitive impairment, hidden by severe deafness, may limit the auditory rehabilitation after successful surgery. It may not be prudent to invest in a cochlear implant in a patient with a very poor prognosis from the outset.

Acknowledgements

The author is a Wellcome Trust Senior Fellow in Clinical Science who also receives research funding support from the United Mitochondrial Diseases Foundation. This chapter was adapted from²¹.

Figure

Pure tone audiograms showing: (A) severe hearing loss across all frequencies in a 44 year old male harboring the mtDNA 3243A>G tRNA Leu^(UUR) mutation; and (B) high-frequency hearing loss in a 56 year old male with Kearns Sayre syndrome due to a single 4.7Kb deletion of mtDNA. Open circles = air conduction, open triangles = bone conduction. dB = decibel hearing loss, ISO = international standards organization. Reproduced with permission from *Oxford University Press, Brain* 2000;123:82-92.



References

1. Leonard JV, Schapira AH. Mitochondrial respiratory chain disorders I: mitochondrial DNA defects. *Lancet*. 2000;355(9200):299-304.
2. McFarland R, Taylor RW, Chinnery PF, Howell N, Turnbull DM. A novel sporadic mutation in cytochrome c oxidase subunit II as a cause of rhabdomyolysis. *Neuromuscul Disord*. 2004 Feb;14(2):162-6.
3. Chinnery PF, Elliot C, Green GR, Rees A, Coulthard A, Turnbull DM, Griffiths TD. The spectrum of hearing loss due to mitochondrial DNA defects. *Brain*. 2000;123:74-81.
4. Chinnery PF, Bindoff LA. 116th ENMC international workshop: the treatment of mitochondrial disorders, 14th-16th March 2003, Naarden, The Netherlands. *Neuromuscul Disord*. 2003 Nov;13(9):757-64.
5. Kemp DT. Stimulated otoacoustic emissions from within the human auditory system. *Journal of the acoustic society of America*. 1978;64:1386-91.
6. Griffiths TD. Central auditory pathologies. *Br Med Bull*. 2002;63:107-20.
7. Griffiths TD. Functional Imaging of Pitch Processing. In: Plack CJ, Oxenham AJ, editors. *Pitch: Neural Coding and Perception*. New York: Springer Verlag; 2005.
8. Elverland HH, Torbergesen T. Audiologic findings in a family with mitochondrial disorder. *Americal Journal of Otology*. 1991;12:459-65.
9. Sue CM, Lipsett LJ, Crimmins DS, Tsang CS, Boyages SC, Presgrave CM, Gibson WPR, Byrne E, Morris JGL. Cochlear origin of hearing loss in MELAS syndrome. *Ann Neurol*. 1998;43:350-9.
10. Yamasoba T, Oka Y, Tsukuda K, Nakamura M, Kaga K. Auditory findings in patients with maternally inherited diabetes and deafness harboring a point mutation in the mitochondrial transfer RNA^{Leu(UUR)} gene. *Laryngoscope*. 1996;106:49-53.
11. Oshima T, Ueda N, Ikeda K, Abe K, Takasaka T. Bilateral sensorineural hearing loss associated with the point mutation in mitochondrial genome. *Laryngoscope*. 1996;106:43-8.
12. Prezant TR, Agapian JV, Bohlman MC, Bu X, Oztas S, Qui W-Q, Arnos KS, Cortopassi GA, Jabier L, Rotter JI, Shohat M, Fischel-Ghodsian N. Mitochondrial ribosomal RNA mutations associated with both antibiotic-induced and non-syndromic deafness. *Nat Genet*. 1993;4:289-94.
13. Yamaguchi T, Himi T, Harabuchi Y, Hamamoto M, Kataura A. Cochlear implantation in a patient with mitochondrial disease--Kearns-Sayre syndrome: a case report. *Adv Otorhinolaryngol*. 1997;52:321-3.
14. Tono T, Ushisako Y, Kiyomizu K, Usami S, Abe S, Shinkawa H, Komune S. Cochlear implantation in a patient with profound hearing loss with the A1555G mitochondrial mutation. *Am J Otol*. 1998 Nov;19(6):754-7.
15. Rosenthal EL, Kileny PR, Boerst A, Telian SA. Successful cochlear implantation in a patient with MELAS syndrome. *Am J Otol*. 1999 Mar;20(2):187-90; discussion 90-1.
16. Yasumura S, Aso S, Fujisaka M, Watanabe Y. Cochlear implantation in a patient with mitochondrial encephalopathy, lactic acidosis and stroke-like episodes syndrome. *Acta Otolaryngol*. 2003 Jan;123(1):55-8.
17. Counter PR, Hilton MP, Webster D, Wardell T, Taylor RW, Besley G, Turnbull DM, Robinson PJ. Cochlear implantation of a patient with a previously undescribed mitochondrial DNA defect. *J Laryngol Otol*. 2001 Sep;115(9):730-2.

18. Sinnathuray AR, Raut V, Awa A, Magee A, Toner JG. A review of cochlear implantation in mitochondrial sensorineural hearing loss. *Otol Neurotol*. 2003 May;24(3):418-26.
19. Thompson VA, Wahr JA. Anesthetic considerations in patients presenting with mitochondrial myopathy, encephalopathy, lactic acidosis, and stroke-like episodes (MELAS) syndrome. *Anesth Analg*. 1997 Dec;85(6):1404-6.
20. Chinnery PF, Turnbull DM. Mitochondrial medicine. *Q J Med*. 1997;90:657-66.
21. Chinnery PF, Griffiths TD. Mitochondrial Otology (Chapter 8). In: *Mitochondrial Medicine*. DiMauro S and Schon EA (eds). Parthenon, London. 2006. pp 161-178. In: DiMauro S, Hirano M, Schon EA, editors. *Mitochondrial Medicine*. London: Parthenon; 2006. p. 161-78.

Table 1. Hearing impairment in mitochondrial disease – genotype and phenotype.

Category		Syndrome	Principal associated features	Molecular defect	Inheritance
Syndromic					
	Multi-systemic	KSS	PEO, ptosis, ataxia, pigmentary retinopathy, heart block.	mtDNA deletion	S
		CPEO	+/- proximal limb weakness	mtDNA deletion or point mutation.	S or M
		MELAS	Seizures, encephalopathy, stroke-like episodes, diabetes mellitus, cardiomyopathy	mtDNA 3243A>G	M
		Leigh syndrome	Relapsing encephalopathy, ataxia, cardiomyopathy, hepatic failure	Nuclear or mtDNA	M or AR
		Encephalomyopathy	Myopathy, diabetes, encephalopathy, ataxia	mtDNA 14709T>C	M
	Oligosyndromic	MIDD	Diabetes mellitus	mtDNA 3243A>G	M
		MIDD	Diabetes mellitus	mtDNA 8296A>G	M
		MDD	Dystonia, cortical blindness, paranoid delusions.	<i>TIMM8A</i>	XLR
		OA	Optic atrophy	<i>OPA1</i>	AD
		MMA	Leigh-like encephalopathy, dystonia	<i>SUCLA2</i>	AR
Non-syndromic (isolated)	Aminoglycoside-induced	D		mtDNA 1555A>G	M
	Non-aminoglycoside induced	D		mtDNA 1555A>G	M
		D		mtDNA 3243A>G	M
		D		mtDNA 7445A>G	M
		D		mtDNA 7472insC	M
		D		mtDNA 7511T>C	M

AD = autosomal dominant, AR = autosomal recessive, CPEO = chronic progressive external ophthalmoplegia, D = isolated (non-syndromic) deafness, KSS = Kearns Sayre syndrome, MELAS = mitochondrial encephalomyopathy with lactic acidosis and stroke-like episodes, MIDD = maternally inherited diabetes and deafness, MMA = methylmalonic aciduria, M = maternal inheritance, OA = optic atrophy, S = sporadic, XLR = X-linked recessive

